TEN TIPS for Optimizing Patients' Experiences with Implants & IUDs

Patty Cason, MS, FNP-BC

Envision Sexual and Reproductive Health

www.envisionsrh.com

patty@envisionsrh.com

Learning Objectives

- Describe why slow technique is a best practice when placing implants and IUDS
- List 3 instruments that facilitate successful IUD placement and removal
- Describe verbicaine

10

Visualize the cervix when faced with challenging anatomy

Choose the Right Speculum

- For IUD placement, choose the shortest speculum possible
- Go wider not longer

In Addition to the Thumb Screw Remember Also to ***Use the Handle Screw***

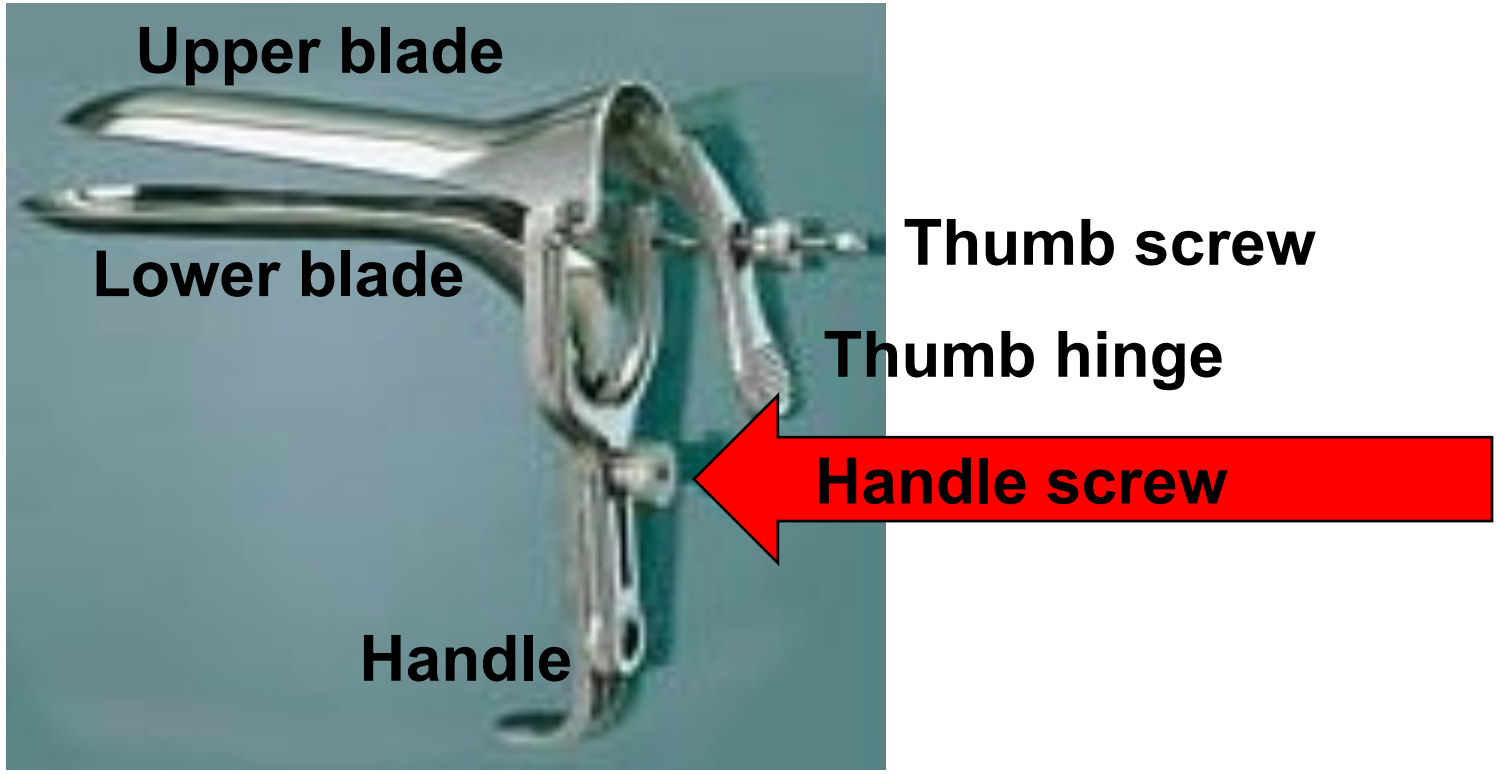

When Speculum Placement is a Challenge: Optimize Position

- Client should be positioned as far down on the exam table as possible to allow maneuvering of the speculum once in place
- Hips over the edge of the exam table drops the pelvis and cervix forward and makes visualization easier

Raise the Buttocks

- Have the client place their hands in a fist under their buttocks
- Lower the head of the table
- Place a lift under the buttocks

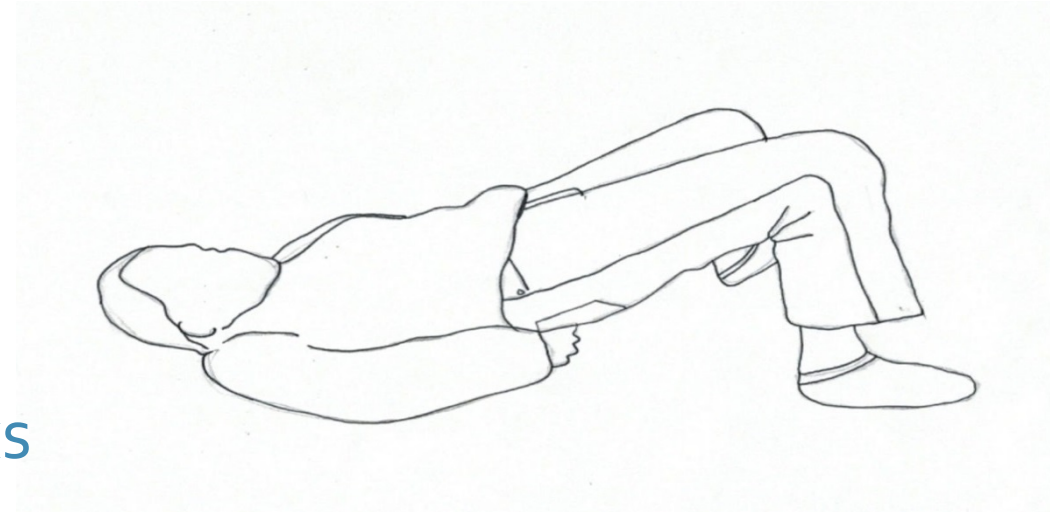

Knees to Chest
or “Cannon Ball”

The client pulls their knees up and back

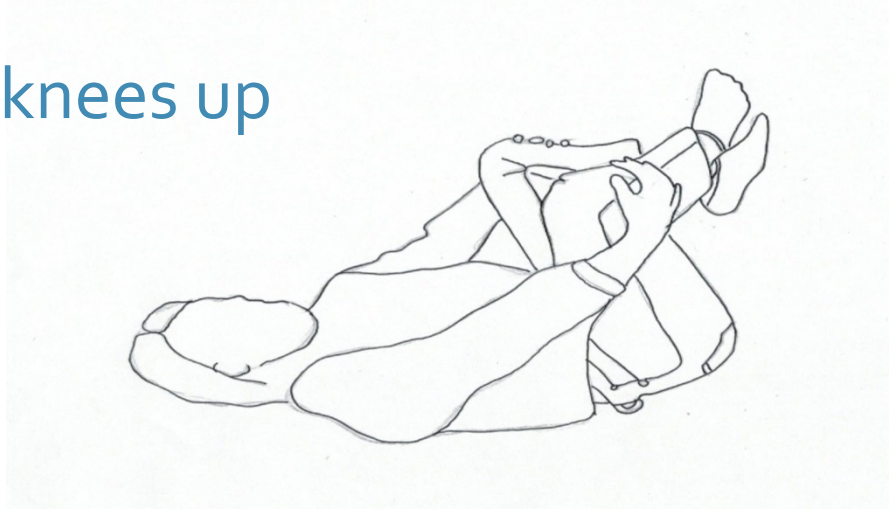

9

Instruments to have on hand that facilitate successful IUD placements and removals

Os Finder Device



Cervical Os Finders (Disposable Box/25)

Cervical Os Finder Set (Reusable Set of 3)

IUD Extraction Without Visible Strings

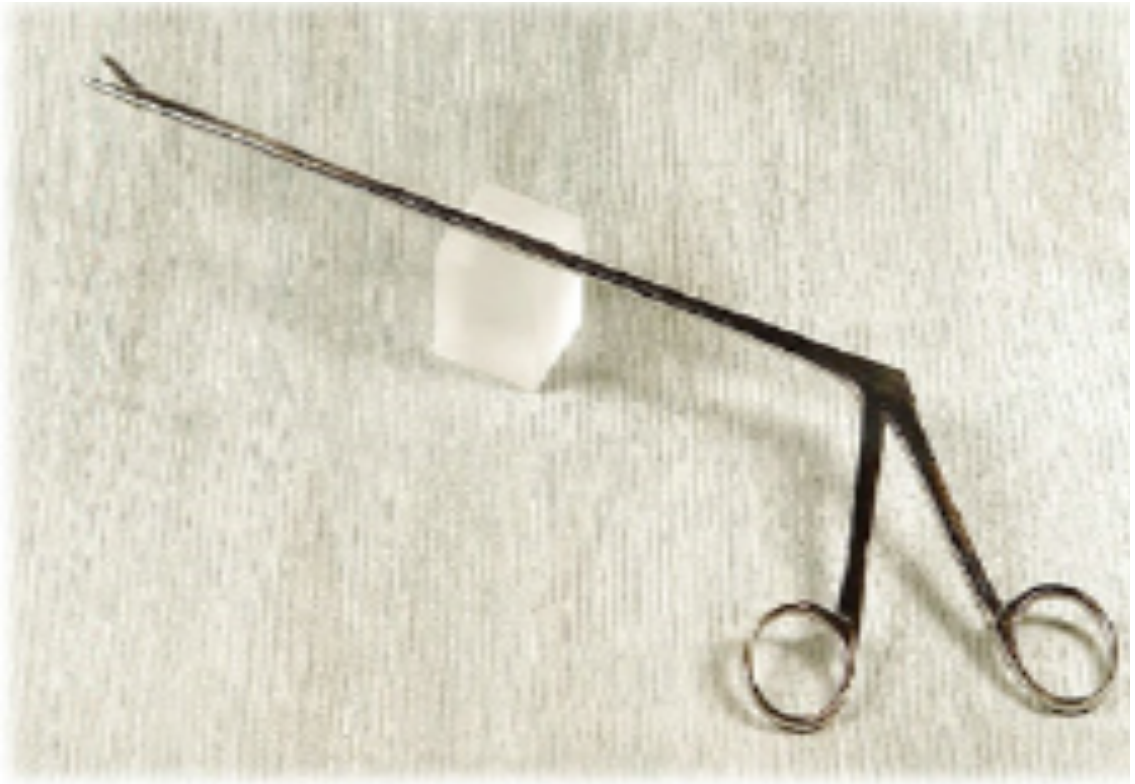

Alligator forceps

(Prabhakaran, 2011)

Thread Retriever



8

Cut strings long and blunt

Cut the Strings for Comfort

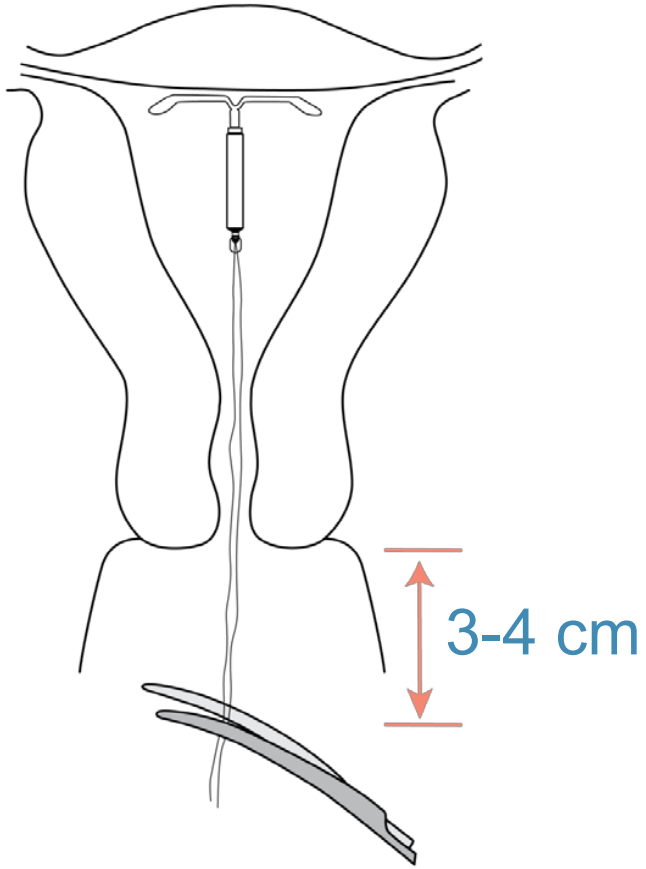

- Use scissors that are:
  - Sharp
  - Blunt-tipped
  - Long
  - Curved
- Cut the strings perpendicular -- cutting threads at an angle may leave sharp ends
- Leave 3-4 cm outside of the cervix

7

Remove implants with the fingers-only technique

https://www.envisionsrh.com/implant-removal-pop-out

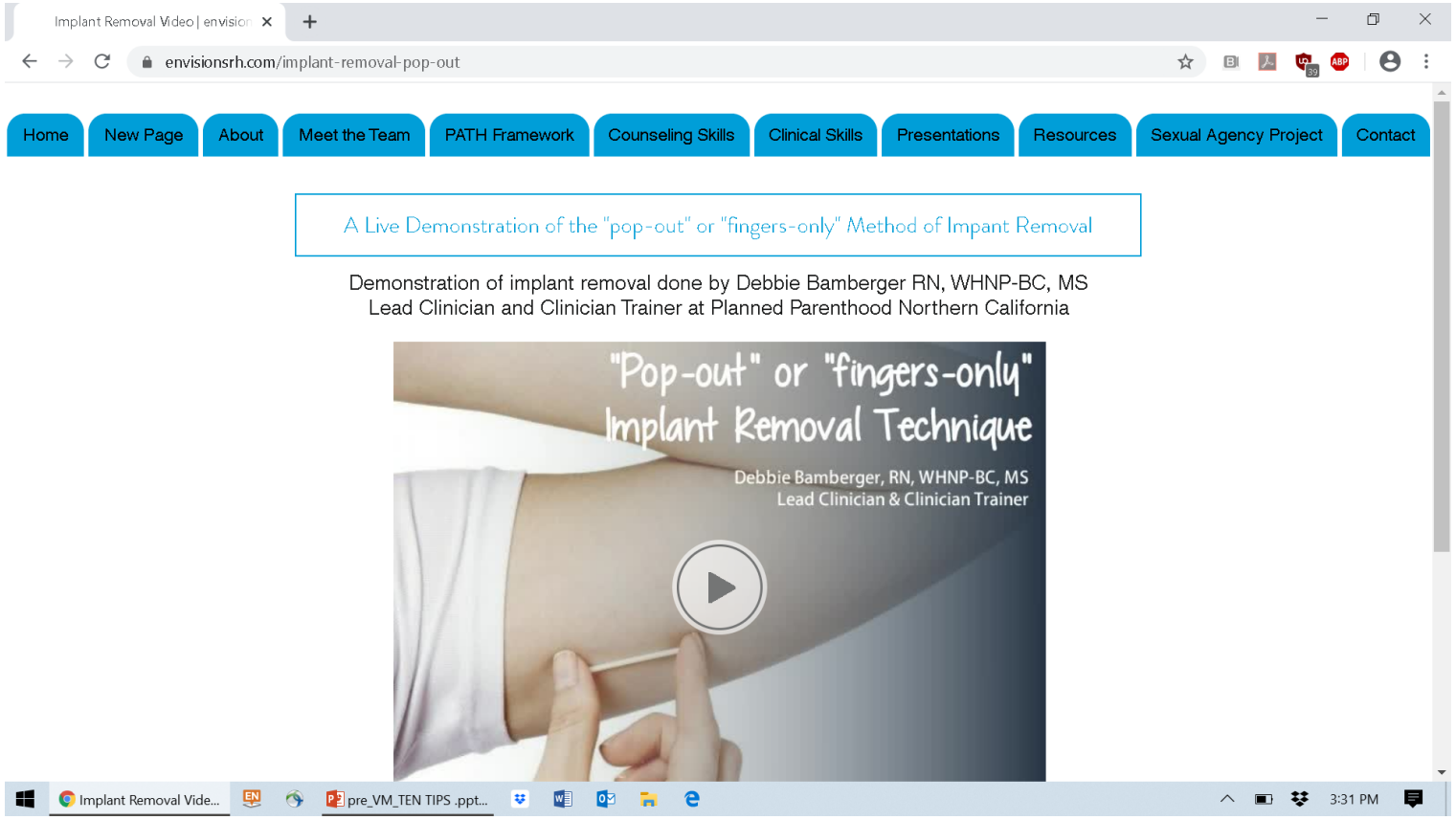

6

Keep pain to a minimum

Verbicaine

Keep the patient talking!

When speaking to the patient avoid words with unpleasant connotations

Calm, soft vocal tone with slow pace

(Carugno, 2020 | Gemzell-Danielsson, 2019 | Hunter, 2020)

Distraction

(Gemzell-Danielsson, 2019 | Hunter, 2020 | Eric, 2020)

Medication

NSAIDs

may reduce placement pain

help with post-placement cramping

Lidocaine prilocaine gel for 7 minutes

Benzodiazepine + Acetominophen + opioid

(Lopez, 2015 | Abbas, 2017)

Cervical Anesthesia

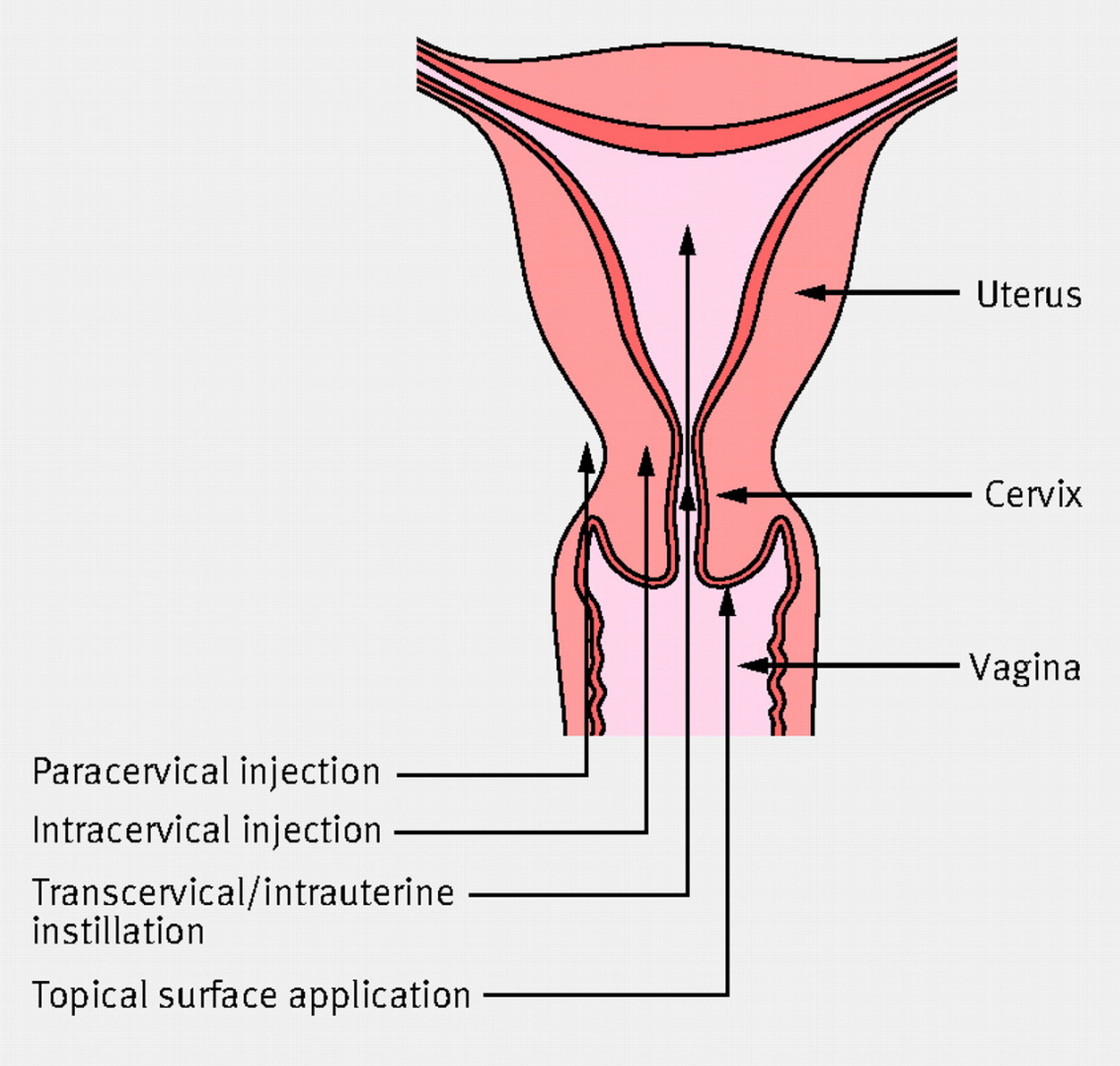

(De Nadai, 2020 | Mody, 2018 | Envall, 2019)

Tenaculum

- Not too deep or wide
- Close the tenaculum very slowly
- 1cc local anesthetic at the site
- Have patient cough at moment of tenaculum placement

(Lambert, 2020 | Gemzell-Danielsson, 2019)

Uterine Sound Pain Reduction

- Move ***slowly***
- Consider endometrial biopsy (EMB) sampler or smaller plastic sound (3mm) for sounding
- Touch the fundus once; repeated tapping is unnecessarily uncomfortable for the patient

5

Place implant atop the tricep

Clinicians are now advised to ***avoid placement in the biceps groove***

Place over the tricep

(Rowland, 2017 | (Ohannessian, 2019 | Simon, 2020)

4

Offer the most effective emergency contraceptive as first line

No Decrease in Efficacy Due to Weight

Off-label Use



3

No barriers to removal

"This device is good for up to __ years, but if you want to get pregnant before that or *if you want it out for any reason*, we will remove it for you and your ability to get pregnant goes back to whatever is normal for you, immediately."

IUD and Implant Removals

- Many providers are reluctant to remove devices because they are so effective
- Clients do not have to justify why they want a device removed from their body
- When discussing placement, even before the client is using the device, let the client know that ***it is their right*** to have it removed at any time!

(Amico, 2017 | Amico, 2016 | Higgins, 2016)

Counseling About IUD and Implant Removals

- If the client presents for removal, begin with assurance that you will remove the device.
- If client has concerns that cause them to want removal, you can respectfully ask client what is concerning to them.
  - This is so you can offer management if the client is open to the conversation (and if there is a management option); or so that you can offer accurate information if the request or concern is based on misinformation.
  - Assess whether there is an alternative cause for the bleeding.
  - Offer options for management of bleeding if appropriate.

(Higgins, 2016)

2

No more fainting

Vasovagal Response

Episode, or Attack AKA: Non-cardiogenic Syncope

- Mechanism
  - Starts with peripheral vasodilation
  - Bradycardia + drop in B/P
- More likely with dehydration or NPO
  - Pain with cervical manipulation
  - Previous episodes of vaso-vagal fainting

(Grubb, 2005)

Pre-syncopal Signs and Symptoms

- Facial pallor (distinct green hue)
- Diaphoresis, feeling warm or cold
- Sudden need to go to the bathroom
- Nausea
- Yawning
- Pupillary dilatation
- Weakness,light-headedness
- Visual blurring/ tunnel vision

How to Avert Vasovagal Syncope

- Isometric contractions of the extremities
- Intense gripping of the arm, hand, leg and foot muscles
- No need to bring the legs together or change position– just tense the muscles
- This stops the reaction

Vasovagal Prevention

- Anticipatory guidance!
- Good hydration
- Eat before placement
- Prophylactically contract muscles if known history

(Grubb, 2005)

1

Slow

Slower

Slowest

SAFETY & SUCCESS with a SOUND



Hold the Sound Like a Dart

Bend the sound to mimic uterine flexion

To Prevent Perforation

- Exert **adequate traction with the tenaculum** to straighten the axis of the uterus when sounding and advancing the inserter
- Use only finger or wrist action… **no elbow or shoulder motion**
- Brace fingertips on speculum to control force while advancing the sound or inserter

Or Like a Pencil

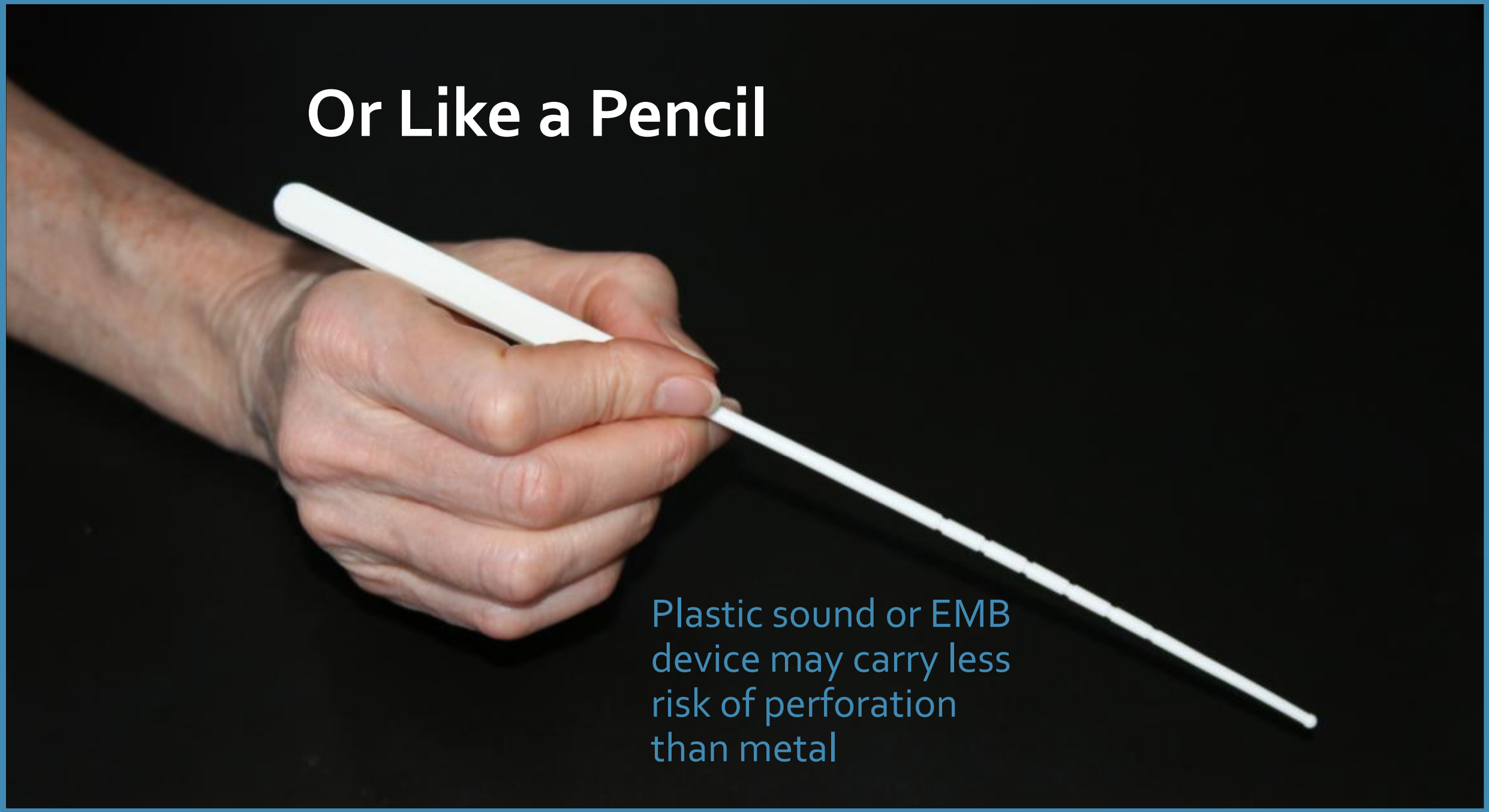

Plastic sound or EMB device may carry less risk of perforation than metal

To Avoid Excessive Force

- Gently hold the sound at the internal os and then wait -- to allow the os to yield
- Apply light pressure at various angles and positions with the sound looking for an opening
- Rather than pushing harder, place cervical block and dilate cervix if resistance is encountered to allow you to ***avoid excessive force*** when advancing the sound and the inserter

To Avoid Momentum

- Don't use force at internal os
- *Slow* progression through the internal os
- **Once you have passed through the internal os, *STOP***
  …then, proceed to the fundus in a controlled fashion
- SLOW movements → safer and less pain

late breaking

Yes: Use of Menstrual Cups ***is*** Associated with IUD Expulsion

(Long, 2020 | Schnyer, 2019 | Seale, 2019)

Comparing IUDs

Brand Name	Skyla®	Kyleena®	Mirena®	Liletta®	CuT
LNG content (mg in reservoir)	13.5	19.5	52	52	0
Release rate (mcg/24 hrs)	14	17.5	20	19.5	0
At end	5	7.4	+/-10	17, 14.8, 12.9, 11.3, 9.8	0
Max duration, years	3	5	5 (7)	6 (7)	10 (12+)
T-frame, mm	28x30	28x30	32x32	32x32	32x36
Insertion tube diameter	3.80	3.80	4.40	4.80	4.75
String color	Brown	Blue	Brown	Blue	White
Silver ring	Yes	Yes	No	No	No

references

- Abbas, A. M., Abdellah, M. S., Khalaf, M., Bahloul, M., Abdellah, N. H., Ali, M. K., & Abdelmagied, A. M. (2017). Effect of cervical lidocaine-prilocaine cream on pain perception during copper T380A intrauterine device insertion among parous women: A randomized double-blind controlled trial. Contraception, 95(3), 251-256.
- Amico, J. R., Bennett, A. H., Karasz, A., & Gold, M. (2016). "She just told me to leave it": Women's experiences discussing early elective IUD removal. Contraception, 94(4), 357-361.
- Amico, J. R., Bennett, A. H., Karasz, A., & Gold, M. (2017). "I wish they could hold on a little longer": physicians' experiences with requests for early IUD removal. Contraception, 96(2), 106-110.
- Carugno, J., Timmons, D., Lederer, M., & Grady, M. M. (2020). Impact of using words with unpleasant emotional connotations on perceived patient discomfort during vaginal speculum examinations: A randomized controlled trial. Eur J Obstet Gynecol Reprod Biol, 247, 203-206.

references

- De Nadai, M. N., Poli-Neto, O. B., Franceschini, S. A., Yamaguti, E. M. M., Monteiro, I. M. U., Troncon, J. K., . . . Vieira, C. S. (2020). Intracervical block for levonorgestrel-releasing intrauterine system placement among nulligravid women: a randomized double-blind controlled trial. *Am J Obstet Gynecol*, 222(3), 245.e241-245.e210.
- Envall, N., Lagercrantz, H. G., Sunesson, J., & Kopp Kallner, H. (2019). Intrauterine mepivacaine instillation for pain relief during intrauterine device insertion in nulliparous women: a double-blind, randomized, controlled trial. *Contraception*, 99(6), 335-339.
- Eric, J., Purut, Y. E., & Harmanci, H. (2020). The Effect of Video Assisted Information on Anxiety and Pain Associated with Intrauterine Device Insertion. *Gynecol Obstet Invest*, 85(1), 82-87.
- Gemzell-Danielsson, K., Jensen, J. T., Monteiro, I., Peers, T., Rodriguez, M., Di Spiezio Sardo, A., & Bahamondes, L. (2019). Interventions for the prevention of pain associated with the placement of intrauterine contraceptives: An updated review. *Acta Obstet Gynecol Scand*, 98(12), 1500-1513.

references

- Grubb, B. P. (2005) Clinical practice. Neurocardiogenic syncope. *N Engl J Med*, 352(10), 1004-1010.
- Higgins, J. A., Kramer, R. D., & Ryder, K. M. (2016). Provider Bias in Long-Acting Reversible Contraception (LARC) Promotion and Removal: Perceptions of Young Adult Women. *Am J Public Health*, 106(11), 1932-1937.
- Hunter, T. A., Sonalkar, S., Schreiber, C. A., Perriera, L. K., Sammel, M. D., & Akers, A. Y. (2020). Anticipated Pain During Intrauterine Device Insertion. *J Pediatr Adolesc Gynecol*, 33(1), 27-32.
- Lambert, T., Truong, T., & Gray, B. (2020). Pain perception with cervical tenaculum placement during intrauterine device insertion: a randomised controlled trial. *BMJ Sex Reprod Health*, 46(2), 126-131.
- Long, J., Schreiber, C., Creinin, M. D., Kaneshiro, B., Nanda, K., & Blithe, D. (2020). Menstrual Cup Use and Intrauterine Device Expulsion in a Copper Intrauterine Device Contraceptive Efficacy Trial [OP01-1B]. *Obstetrics & Gynecology*, 135, 1S. doi:10.1097/01.aog.0000662872.89062.83

references

- Lopez, L. M., Bernholc, A., Zeng, Y., Allen, R. H., Bartz, D., O'Brien, P. A., & Hubacher, D. (2015). Interventions for pain with intrauterine device insertion. *Cochrane Database Syst Rev*, 7, Cd007373.
- Mody, S. K., Farala, J. P., Jimenez, B., Nishikawa, M., & Ngo, L. L. (2018). Paracervical Block for Intrauterine Device Placement Among Nulliparous Women: A Randomized Controlled Trial. *Obstet Gynecol*, 132(3), 575-582.
- Ohannessian, A., Levy, A., Jaillant, N., Tanguy Le Gac, Y., D'Journo, X., Vidal, V., & Agostini, A. (2019). A French survey of contraceptive implant migration to the pulmonary artery. *Contraception*, 100(4), 255-257. doi:10.1016/j.contraception.2019.05.016
- Prabhakaran, S., & Chuang, A. (2011). In-office retrieval of intrauterine contraceptive devices with missing strings. *Contraception*, 83(2), 102-106.
- Rowlands, S., Mansour, D., & Walling, M. (2017). Intravascular migration of contraceptive implants: two more cases. *Contraception*, 95(2), 211-214.

references

- Schnyer, A. N., Jensen, J. T., Edelman, A., & Han, L. (2019). Do menstrual cups increase risk of IUD expulsion? A survey of self-reported IUD and menstrual hygiene product use in the United States. *Eur J Contracept Reprod Health Care*, 24(5), 368-372. doi:10.1080/13625187.2019.1643836
- Seale, R., Powers, L., Guiahi, M., & Coleman-Minahan, K. (2019). Unintentional IUD expulsion with concomitant menstrual cup use: a case series. *Contraception*, 100(1), 85-87. doi:10.1016/j.contraception.2019.03.047
- Simon, C., Maurier, A., Gaboriau, L., Vrignaud, L., Dayani, P., Vaillant, T., . . . Pierre Jonville-bera, A. Incidence and characteristics of intravascular pulmonary migration of etonogestrel implants: a French nationwide study. *Contraception*. doi:10.1016/j.contraception.2020.05.006